

Management of Myofascial Pain Syndrome in the Masseter Muscle Triggered by Pericoronitis: A Case Report

Perikoronit Tarafından Tetiklenen Masseter Kasındaki Miyofasyal Ağrı Sendromunun Tedavisi: Vaka Raporu

 **Elif Tuba Akçin**

Department of Prosthodontics, Lokman Hekim University Faculty of Dentistry, Ankara, Türkiye

Abstract

Temporomandibular disorders, which are more common in women between 20 and 50 years of age, are not rare in dentistry. Myofascial pain syndrome in the masticatory muscles is characterized by pain and restriction of mouth opening, and it usually occurs due to a parafunctional habit such as bruxism or teeth clenching. In the presence of dental caries and/or periodontal diseases, the severity of parafunctional habits may increase, causing acute myofascial pain syndrome attack. In the presence of complex factors, the treatment protocol may differ. Encouraging outcomes can be obtained if both dental treatments and the elimination of parafunctional habits are carried out together. This case report presents the complex treatment of myofascial pain syndrome in the masticatory muscles triggered by pericoronitis in the right mandibular third molar tooth.

Keywords: Case report; Myofascial pain syndrome; Pericoronitis; Temporomandibular disorders

Myofascial pain syndrome is characterized by regional pain, limited range of motion, and localized muscle tenderness. Also, it is a common condition in dentistry with a prevalence ranging between 10% and 68% with temporomandibular disorders.^[1,2] This syndrome is more commonly seen in females, especially between the ages of 20 and 50 years.^[3,4]

Myofascial pain syndrome in masticatory muscles is one of the temporomandibular disorders and is usually triggered by a parafunctional habit like bruxism or teeth clenching.

Bruxism is characterized by the continuous application of force through the masticatory muscles by bringing the teeth into occlusion during sleep, and teeth clenching may accompany.^[5] Heavy forces on teeth caused by bruxism and teeth clenching result in destruction in surrounding soft tissues, masticatory muscle spasms and pains, and resorption in alveolar crestral bones. In the presence of teeth grinding, the destructive effect of horizontal forces on periodontal tissues increases even more. As well, bruxism and teeth clenching fasten the destruction caused by

Cite this article as: Akçin ET. Management of Myofascial Pain Syndrome in the Masseter Muscle Triggered by Pericoronitis: A Case Report. Lokman Hekim Health Sci 2023;3(2):149–152.

Correspondence: Elif Tuba Akçin, DDS. Lokman Hekim Üniversitesi Diş Hekimliği Fakültesi, Protetik Diş Tedavisi Anabilim Dalı, Ankara, Türkiye

E-mail: tuba.akcin@lokmanhekim.edu.tr **Submitted:** 05.12.2022 **Revised:** 13.12.2022 **Accepted:** 09.02.2023

OPEN ACCESS This is an open access article under the CC BY-NC license (<http://creativecommons.org/licenses/by-nc/4.0/>).



chronic inflammation such as gingivitis, periodontitis, and pericoronitis. Conversely, toothache caused by tooth decay and periodontal diseases may trigger teeth clenching or increases the severity of the existing habit. There is a positive relationship between myofascial pain and toothache which affects each other.^[6] The diagnosis of myofascial pain syndrome in masticatory muscles has been challenging for clinicians. Also, the causes of the disease are complex, and detecting the main reason is essential.

In this case report, the management of the acute attack of myofascial pain syndrome triggered by the pain caused by pericoronitis in the mandibular third molar tooth with half mucosal retention is presented. Herein, we will highlight the strong relationship between toothache and myofascial pain syndrome.

Patient Information

A 34-year-old female patient applied to our clinic with masticatory muscle pain and restriction of mouth opening. The patient suffered the pain for 2 years. There are no systemic diseases in medical history. The patient was treated with botulinum toxin application in the masseter and temporal muscles 1 year ago, which ensured a short time relaxation, but the pain started again in a few months. Now, the pain is resistant to nonsteroidal anti-inflammatory drugs (NSAIDs), causes insomnia.

Clinical Findings

In the extraoral examination, no crepitation or clicking was detected in temporomandibular joints during jaw movements. No deflection or deviation was determined during mouth opening. Swelling on the right side of the face and severe pain in masticatory muscles (especially the masseter) was detected. Moreover, the right masseter muscle was more sensitive to palpation. The mouth opening was measured as 30 mm, and it increased with finger pressure (soft end feel) (Fig. 1a, b). In the intraoral examination, hyperemia was detected at the mucosa covering half of the right mandibular third molar tooth and associated gingiva. Also, tooth decay and bone destruction were detected in the distal part on panoramic radiographs (Fig. 2). Patient history and clinical examination findings are listed in Table 1.

Diagnostic Assessment and Therapeutic Intervention

After clinical examination and radiological evaluation, the patient, who was previously diagnosed with bruxism, was diagnosed with an acute myofascial pain syndrome attack due to pericoronitis occurring in the right mandibular third molar tooth.

Table 1. Patient history and clinical examination findings

| Patient history and clinical examination findings | |
|---|--|
| Age | 34 |
| Sex | Female |
| Complaint | Myofascial pain in the masseter muscle Limitation in mouth opening Pain during chewing function Insomnia due to pain |
| Onset of pain | 2 years earlier |
| Previous treatments | NSAIDs (Non-steroid anti-inflammatory drugs) Botulinum toxin injection into the masseter and temporal muscles |
| Extra oral examination | Healthy temporomandibular joints (no clicking or crepitation) No deviation of deflection during mouth opening Limitation in mouth opening (30 mm) with soft end feel Pain on palpation of the bilateral masseter and temporal muscles |
| Intraoral examination | Hyperemic gingiva around the mandibular third molar tooth |
| Radiological examination | Crestal bone loss distal to the mandibular third molar |

Table 2. Treatment protocol

| | |
|---------------------------|---|
| Pharmacotherapy | Combined antibiotics NSAIDs Intramuscular muscle relaxant |
| Interventional treatments | Muscle relaxation appliance therapy Extraction of the right mandibular third molar tooth Botulinum toxin injection into the masseter muscle |

The patient was prescribed an oral combination of antibiotics, NSAIDs, and muscle relaxant drugs. To make the muscle relaxation splint, maxillary and mandibular impressions were made with alginate, and occlusal contacts of the jaws were recorded with closing wax. Gypsum models obtained from the impressions were taken to the articulator. Auto-polymerization of hard acrylic resin was done according to the manufacturer's recommendations and placed on the maxillary teeth. The thickness of the acrylic resin was 2 mm on the occlusal surfaces of the posterior teeth and 6 mm on the palatal surface of the anterior teeth. To increase the retention time of the splint, the palatal borders were widened to cover the palatal soft tissue up to 10 mm gingiva of the teeth. After the polymerization of the acrylic, finishing

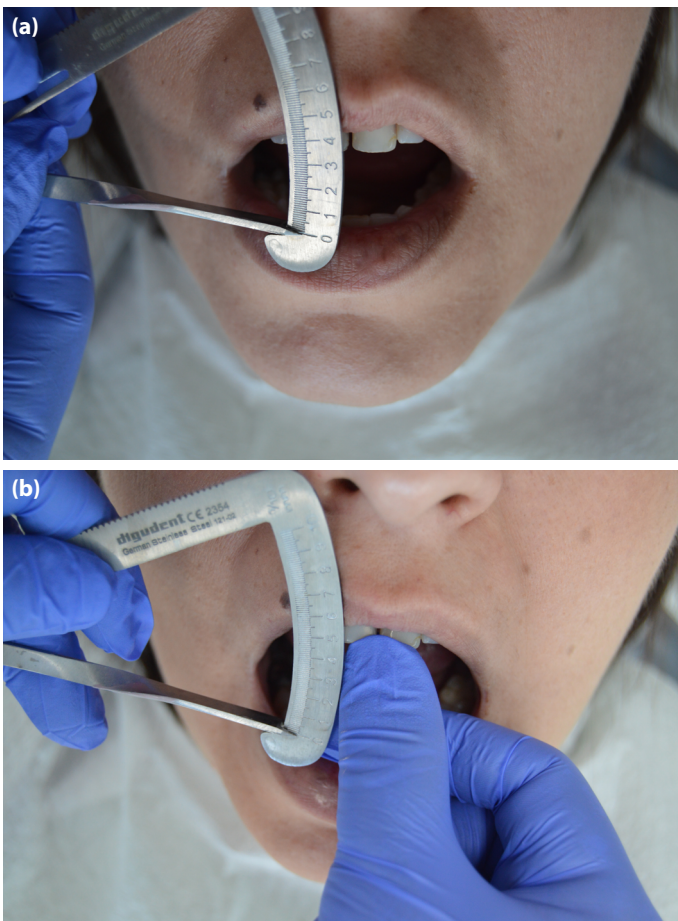


Figure 1. (a) Limitation in mouth opening; (b) increased mouth opening with finger pressure (soft end feel).

and polishing processes were carried out. After clinical testing, the muscle relaxation splint was applied to the patient (Fig. 3). The patient was advised to wear the splint while sleeping and to follow a soft diet. After oral antibiotic use, the right mandibular third molar tooth was extracted under local anesthesia (Fig. 4). Additionally, botulinum toxin injection was applied to the masseter muscle. The treatment protocol is listed in Table 2.

Follow-Up and Outcomes

The acute myofascial pain syndrome attack healed, and the patient felt relieved after tooth extraction, botulinum toxin injection, and using a muscular relaxation splint appliance for 3 weeks. Also, mouth opening limitation is eliminated (Fig. 5). All complaints of the patient were eliminated at the follow-up examination at the sixth month.

Discussion

It is important to detect whether the pain that occurs in temporomandibular disorders is of dental origin or is related to the masticatory muscles. The muscle pain due to teeth clenching

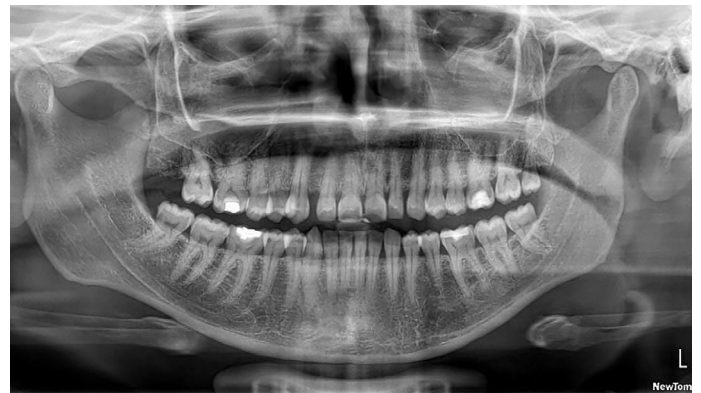

Figure 2. Initial panoramic radiography.

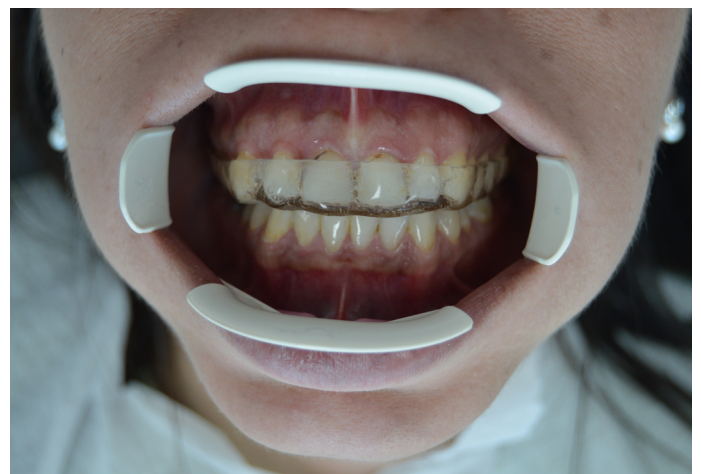

Figure 3. Muscular relaxation appliance in place.

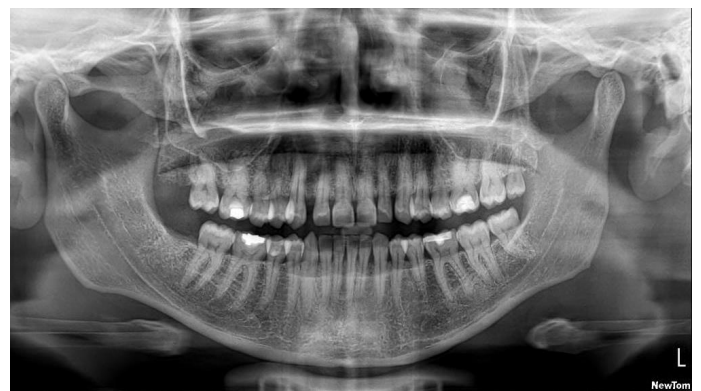

Figure 4. Panoramic radiography after extraction of the right mandibular third molar tooth.

may confuse with a toothache and lead to irreversible dental treatments.^[7] Pain due to dental diseases such as dental caries and pericoronitis can also trigger the pain of masticatory muscles or increase the severity of the existing pain.^[6,7]

Palpation is one of the most appropriate examination methods when diagnosing myofascial pain syndrome. Also, it is one of the most important factors in distin-

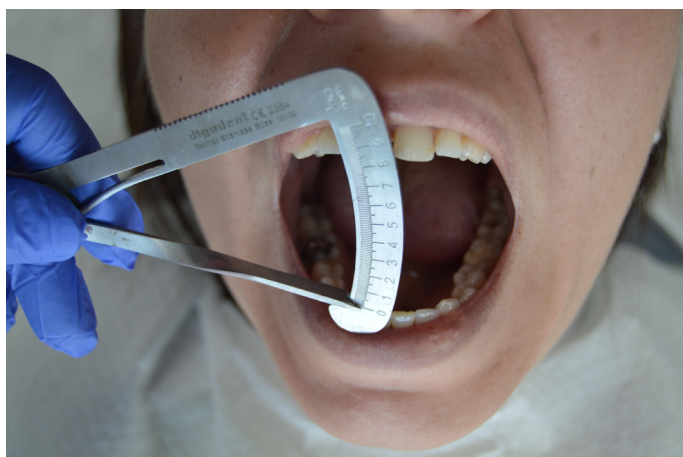

Figure 5. Elimination of mouth opening limitation.

guishing pain in the masticatory muscles from toothache. With the palpation method, trigger points in the muscles can be detected, and the patient can be warned against movements that may initiate myofascial pain by stimulating the trigger points.

Treatment of myofascial pain syndrome includes relaxant spray application on trigger points and stretching, injection to trigger points, pharmacotherapy, appliance therapy, psychological relaxation, and physiotherapy.^[8,9] Muscular relaxant drugs and NSAIDs not only relieve the patient's pain but also increase the quality of sleep. Although the exact mechanism of action of appliances is not known, it is recommended for myofascial pain syndrome.^[5,8]

Additionally, botulinum toxin was injected into the masseter and temporal muscles. Botulinum toxin not only eliminates the problem of muscle contraction and pain instantly but also prevents and delays the recurrence of the syndrome in the long run. It has analgesic effects on pain stages by inhibiting the release of nociceptive mediators, and its mechanism is independent of its neuromotor effects.^[10]

Patient Perspective

All complaints of the patient were eliminated at the follow-up examination at the sixth month. The patient is satisfied with the treatments and the results of the interventions.

Conclusions

In light of all this information, the requirement for a multidisciplinary approach for patients with myofascial pain syndrome emerges. In this case, an acute attack of

myofascial pain syndrome triggered by pericoronitis is presented. Both tooth extraction and application of myofascial pain syndrome treatment protocol eliminated the patient's complaints.

Peer-review: Externally peer-reviewed.

Informed Consent: Written informed consent was obtained from patient who participated in this study.

Conflict of Interest: None declared.

Financial Disclosure: The author declared that this study received no financial support.

References

1. Donnelly JM, Fernández-De-Las-Peñas C, Finnegan M, Freeman JL, Travell, Simons & Simons' Myofascial Pain and Dysfunction: The Trigger Point Manual. Wolters Kluwer; 2018.
2. De la Torre Canales G, Bonjardim LR, Poluha RL, Carvalho Soares FF, Guarda-Nardini L, Conti PR, et al. Correlation between physical and psychosocial findings in a population of temporomandibular disorder patients. *Int J Prosthodont* 2020;33(2):155–9. [\[CrossRef\]](#)
3. Kleinknecht RA, Mahoney ER, Alexander LD. Psychosocial and demographic correlates of temporomandibular disorders and related symptoms: an assessment of community and clinical findings. *Pain* 1987;29(3):313–24. [\[CrossRef\]](#)
4. Pullinger AG, Seligman DA, Solberg WK. Temporomandibular disorders. Part I: Functional status, dentomorphologic features, and sex differences in a nonpatient population. *J Prosthet Dent* 1988;59(2):228–35. Erratum in: *J Prosthet Dent* 1988;60(1):132. [\[CrossRef\]](#)
5. Okeson JP. Management Of Temporomandibular Disorders And Occlusion. Mosby;2008.
6. Aslan Y, Akçin ET. Temporomandibular sorunlarda tanı ve tedavi. In: Çağlayan G, editor. Peridontoloji ve İmplantoloji. 1st ed. Quintessence; 2018. p.373–80.
7. Farella M, Michelotti A, Gargano A, Cimino R, Ramaglia L. Myofascial pain syndrome misdiagnosed as odontogenic pain: a case report. *Cranio* 2002;20(4):307–11. [\[CrossRef\]](#)
8. Kalladka M, Thondebhavi M, Ananthan S, Kalladka G, Khan J. Myofascial pain with referral from the anterior digastric muscle mimicking a toothache in the mandibular anterior teeth: a case report. *Quintessence Int* 2020;51(1):56–62.
9. de Leeuw R, Klasser GD. Orofacial Pain: Guidelines for Assessment, Diagnosis, and Management, (AAOP The American Academy of Orofacial Pain). Chicago: Quintessence; 2013.
10. Matak I, Bölcskei K, Bach-Rojecky L, Helyes Z. Mechanisms of botulinum toxin type a action on pain. *Toxins (Basel)* 2019;11(8):459. [\[CrossRef\]](#)